

**TITLE: Influence of ACL Reconstructive Surgery on Tibiofemoral and Patellofemoral Kinematics: A Dynamic MRI Study**

**AUTHORS:** Kaiser, Jarred<sup>1</sup>; Monawer, Arezu<sup>1</sup>; Kijowski, Rick<sup>2</sup>; Baer, Geoffrey<sup>3</sup>; Thelen, Darryl<sup>1,4</sup>

**INSTITUTIONS:** 1. Dept. of Mechanical Engineering, University of Wisconsin, Madison, WI

2. Dept. of Radiology, University of Wisconsin, Madison, WI

3. Dept. of Orthopedics and Rehabilitation, University of Wisconsin, Madison, WI

4. Dept. of Biomedical Engineering, University of Wisconsin, Madison, WI

**CURRENT PRIMARY CATEGORY:** Knee - Kinematics and Gait

**AWARDS:**

**KEYWORDS:** ACL, Knee Kinematics, Dynamic Imaging

**Introduction:** ACL-reconstructive surgery is highly successful at restoring joint stability and allowing for physical activity (6). However long-term outcomes are less favorable, with >50% of patients exhibiting radiographic signs of osteoarthritis (OA) at 10 year follow-ups (4). Biomechanical studies have previously shown that ACL-reconstructed knees often exhibit subtle abnormalities in secondary joint kinematics during walking and running (8-10). However, it remains unclear whether these abnormal kinematics contribute to early onset OA. Recent advances in quantitative MRI technologies can detect signs of osteoarthritis much earlier than traditional radiographs (1), which could allow for further study of the links between altered joint mechanics and OA development. This study was undertaken to ascertain if altered knee kinematics could be detected in reconstructed knees using with emerging dynamic MRI technologies. We recently introduced a dynamic MR technique which obtains cine volumetric images of the knee with high spatial and temporal resolution (3). We used the technology to test the hypothesis that subtle differences in tibiofemoral and patellofemoral kinematics would be seen in subjects with ACL-reconstructions who perform a simple loaded knee-flexion extension task.

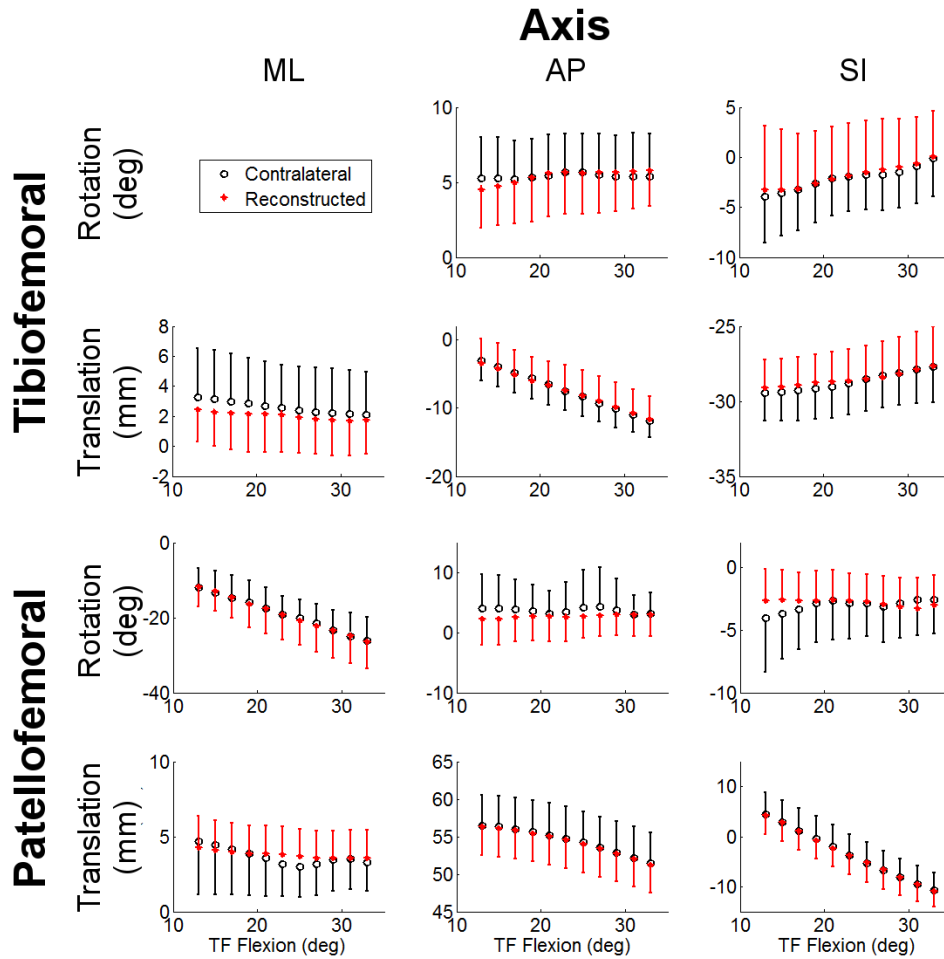
**Methods:** The healthy and ACL-reconstructed knees of seven subjects were tested after obtaining informed consent according to an IRB-approved protocol (5 M, 26.3 +/- 5.3 yrs, 82.3 +/- 13.6 kg, 1.75 +/- 0.09 m, 2.1 +/- 0.8 yrs post-surgery, 4 patellar tendon grafts, 3 hamstring grafts, 2 subjects with partial lateral meniscectomy). Subjects had no history of inflammatory or crystalline induced arthritis, no history of pain, injury, or surgery to the contralateral knee, no additional ligament injury requiring surgical intervention, and no post-operative complications. Subjects laid supine on a loading device and performed cyclic knee flexion-extension at a rate of 0.5 Hz. An inertial load was used to induce eccentric quadriceps contraction with knee flexion, which mimics knee behavior during the load acceptance phase of gait. The five minute task was first performed in a laboratory setting where knee flexion angle, knee torque and upper leg EMG were collected. The task was then repeated within one week in a 3T MRI scanner. A spoiled gradient-echo sequence with vastly under-sampled isotropic projects (SPGR-VIPR) continuously acquired 3D volumetric image data during the task. Images were binned based on knee flexion and retrospectively reconstructed into 60 frames over a 2 s cycle. High resolution models of the tibia, femur, and patella were separately segmented from a high resolution, static SPGR sequence. Local bone reference frames were automatically generated from inertial and geometric properties (5; 7). Bones were optimally registered to each dynamic image. Six degree of freedom tibiofemoral (TF) and patellofemoral (PF) kinematic patterns over the motion cycle were computed. Kinematic trajectories were interpolated at every 2 degrees of knee flexion at knee angles that all subjects traversed (13-33 deg). A two-way repeated measure analysis of variance (ANOVA) was used to assess the effects of limb (reconstructed, contralateral) and knee flexion angle on both TF and PF kinematics. Significance was set at  $p < 0.05$  for inter-limb differences and  $p < 0.1$  for limb-by-flexion angle differences.

**Results:** There were significant limb-by-flexion angle differences observed in TF adduction, anterior tibia translation, and superior tibia translation, with the reconstructed knee biased toward adduction and superior translation in more extended postures. There were also significant limb-by-flexion angle differences in PF medial shift.

**Discussion:** Using an MR-compatible loading device and a novel dynamic MRI sequence, we were able to elicit and measure some significant tibiofemoral and patellofemoral kinematic differences in ACL-reconstructed knees. These kinematic differences are generally consistent with observations made using biplane fluoroscopy, where an increase in tibiofemoral adduction and anterior translation during walking are observed (8). Further, a medial PF shift with quadriceps loading has been seen in cadaveric simulations of ACL reconstructions (2). Notably, we did not consistently see an increase in external tibia rotation, as has been observed previously reported during decline running (9). However, five of the seven subjects did exhibit a shift toward external tibial rotation of 0.5-3°, suggesting that more subjects may be needed to see significance. Further, our subject population had varying graft types and meniscal health, which could obscure population-level differences. However, MRI provides exception soft tissue contrast that can potentially be used to characterize individual differences in graft position/orientation, bone geometry, and cartilage morphology, which could be leveraged to help explain variations in kinematics on an individual basis. Further, the technique can be coupled with quantitative MRI to rigorously investigate the inter-relationship between reconstructive surgery, knee mechanics and early onset OA.

**Significance:** Subtle differences in reconstructed knee kinematics can be measured using dynamic MRI techniques, which can enable longitudinal studies of OA development following ligament repair.

**Acknowledgements:** NIH AR062733, EB015410



**Figure 1:** Tibiofemoral (top) and patellofemoral (bottom) secondary kinematics of the ACL-reconstructed (red) and healthy contralateral (black) knees during flexion.

**References:**

1. Dunn, TC, et al. *Radiology* **232**: 592. 2004.
2. Hsieh, YF, et al. *Am J Sports Med* **26**: 9. 1998.
3. Kaiser, J, et al. *Mag Res Med* **7**. 2013.
4. Liden, M, et al. *Arthroscopy* **24**: 10. 2008.
5. Miranda, DL, et al. *J Biomech* **43**: 4. 2010.
6. Otto, D, et al. *Am J Sports Med* **26**: 181-188. 1998.
7. Rainbow, MJ, et al. *J Biomech*. 2013.
8. Scanlan, SF, et al. *J Biomech* **43**: 1817-1822. 2010.
9. Tashman, S, et al. *Clin Orthop Relat Res* **454**: 66-73. 2007.
10. Webster, KE, et al. *Gait & Posture*. 2012.